



# Acute Assessment of Portal Vein Patency Using Intraparenchymal Carbon Dioxide and a 25 ga Spinal Needle

Christian A. Fauria,MD, Bruce Bordlee,MD and James Caridi, MD

## INTRODUCTION:

There are a myriad of causes of portal vein thrombosis (PVT) including, abdominal visceral cancer, infection and inflammatory processes. Patients with the highest risk of portal vein thrombus (PVT) are those with cirrhosis and hepatocellular carcinoma (HCC) 2. Although portal vein thrombosis can result in cavernous transformation, varices, ascites, encephalopathy and GI bleeding, the most significant sequela post thrombosis in those with HCC is preclusion from liver transplantation.

HCC is the 3rd most common cause of cancer related death and the 6th most common malignancy worldwide6,4. Liver transplant (LT) is considered definitive treatment of HCC, but only acceptable within certain parameters. These are included in the Milan and the more liberal UCSF criteria for liver transplantation4,5. Regarding treatment, the most widely accepted staging system designed to indicate the best treatment option, including LT, is the Barcelona Clinic Liver Cancer (BCLC) system. It stratifies the best treatment option considering the patient's stage of hepatic disease and according to the expected outcome4.

Liver transplant is the treatment of choice, and occasionally the only reasonable treatment option, in patients with acute and chronic liver failure from all causes. Unfortunately, there are a finite number of transplantable livers at any given time in a given location. These circumstances add an additional layer of ethical dilemma when choosing an appropriate candidate for liver transplant.

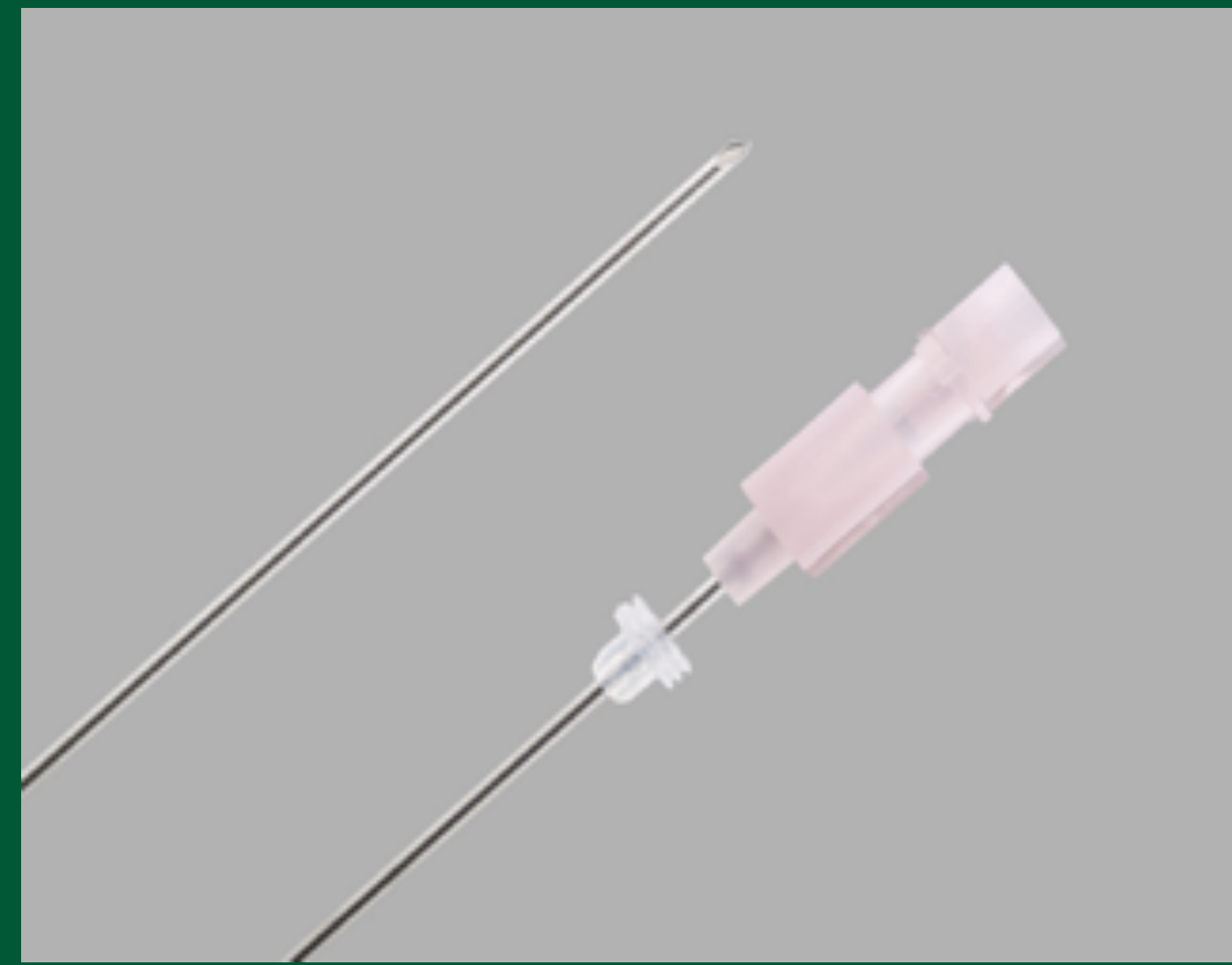Macrovascular invasion is considered tumoral invasion into the portal and/or hepatic veins causing tumor thrombus, detected radiographically or through pathologic specimen. In HCC portal vein tumor thrombosis (PVTT) is an independent measure of tumor burden, thus changing treatment options and management pathways for HCC.1,5 Based on the BCLC staging system macrovascular tumor invasion is an absolute contraindication for liver transplant. Even if tumor invasion is not the cause, bland portal vein thrombosis excludes surgery.

Three or four phase imaging is essential to the diagnosis and treatment planning for HCC. Standard cross-sectional imaging techniques can still under or overestimate the extent of HCC in up to 25% of cases compared with pathologic findings in the explanted liver5, "rarely, 3D imaging has failed to diagnose certain patency of the portal vein prior to transplant"3. Typically, there is a window of opportunity for liver transplantation and it is essential to know acutely the status of the portal vein. On the rare occasion that patency is questionable, comorbid conditions like ascites and coagulopathy make more invasive interventional diagnosis less desirable and often risky.

In our institution, a transplant center, we have been able to aid the surgeons by obtaining a definitive diagnosis despite the limitations inherent to the patient population. In this scenario the right hemi abdomen is prepped and draped, local anesthetic administered and a 25 ga. is placed with impunity into the liver parenchyma disregarding the ascites or the coagulopathy. Injection of 10-20 cc carbon dioxide (CO2) can determine the critical presence or absence of patency of the portal vein"3.

## MATERIALS AND METHODS:

In a retrospective study of 5 patients (2 males, 3 females), all with known HCC, ascites, and equivocal portal vein patency by 3 D imaging, a 25 gauge spinal needle (Cook Medical, Bloomington, IN) was inserted into the liver parenchyma without correcting either the ascites or coagulopathy (INR as high as 0.9-2.4). Using the CO2mmander and AngiAssist delivery system (AngioAdvancements, Fort Meyers, FL) approximately 10-20 cc of pharmaceutical grade CO2 was administered through the spinal needle directly into the hepatic parenchyma to assess patency of the portal venous system. DSA images were obtained at 6 frames per second. The patients received a liver transplant based on the angiographic assessment.



Other equipment used:

CO2: Its low viscosity (1/400th of IV contrast) is what allows this procedure to be a viable option in this population. The Silver Bullet: We use medical grade CO2, a disposable source (cylinder).



AngiAssist [AngioAdvancements, Fort Meyers, FL]: A reservoir and delivery syringe with a one-way valve on the receiving and delivery end of the tubing. CO2 goes to the reservoir syringe and one way valve prevents back flow.

CO2mmander® [Portable Medical Devices, Inc., Ft. Myers, FL]: The CO2mmander® provides a portable, safe, and convenient source of carbon dioxide gas where small volumes of CO2 are needed.



The liver is accessed percutaneously with a 25 ga. Injection of 10-20 cc's CO2 injection can determine the critical presence or absence of patency of the portal vein.

## RESULTS:

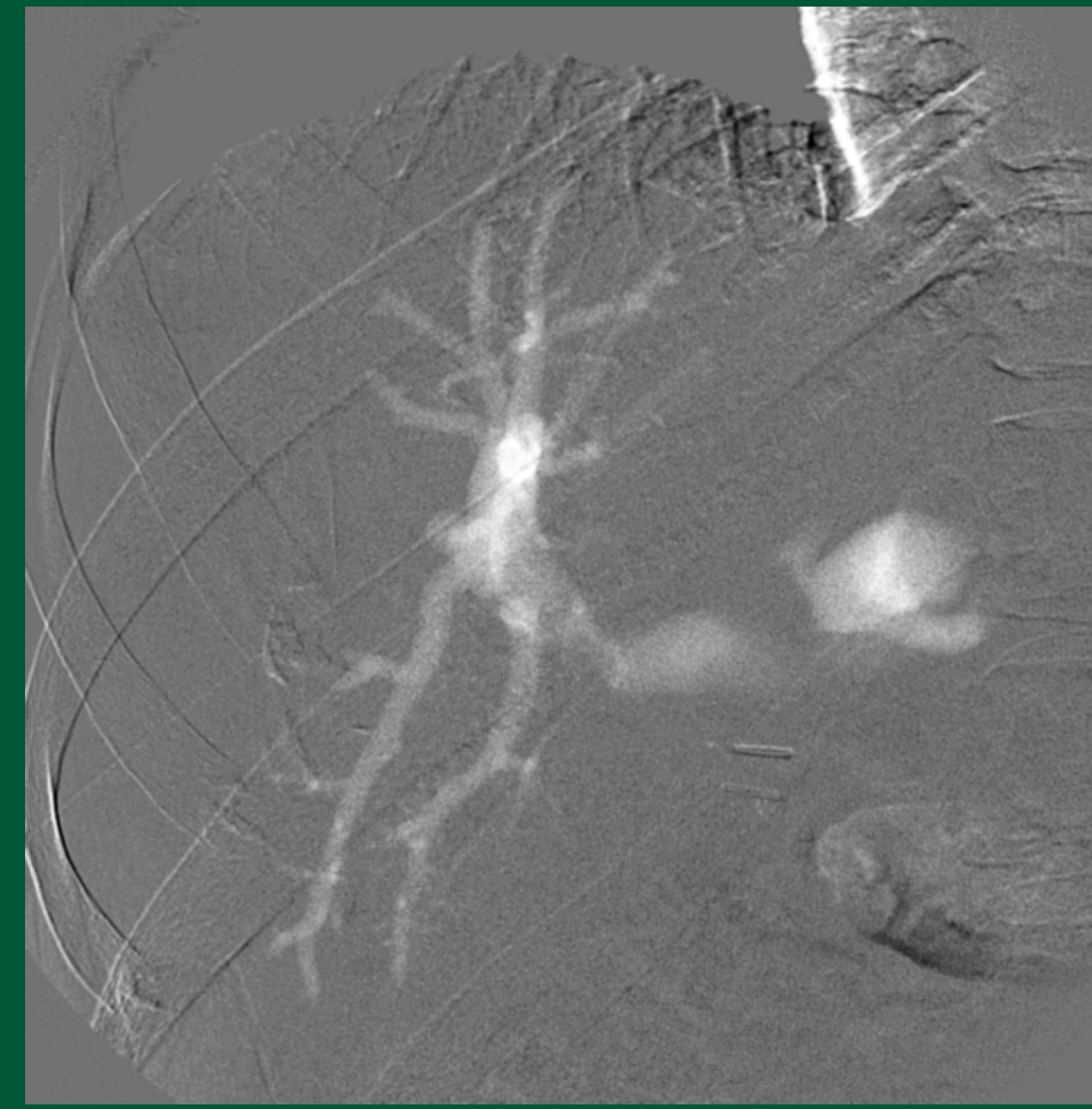

Figure 1: Transhepatic CO2 injection of 20cc's through a 25 ga needle, ascites and elevated INR present and not corrected. Image demonstrates patent portal venous system.

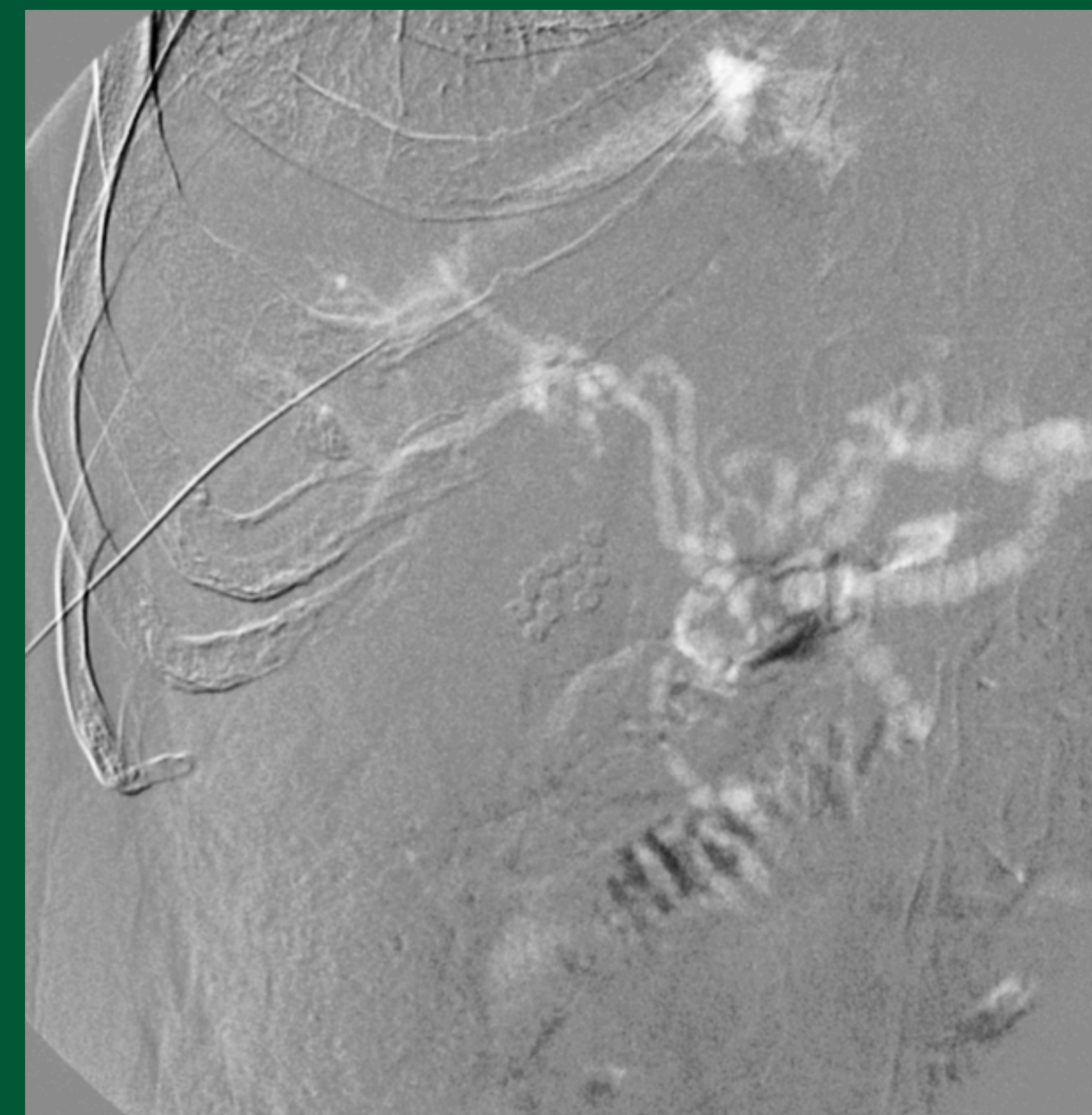


Figure 2: Transhepatic CO2 injection of 20cc's through a 25 ga. needle, ascites and elevated INR present and not corrected. Image demonstrates "cavernous transformation" or tortuous collaterals and occlusion of the portal vein

## DISCUSSION:

Patency of the portal vein is essential to receiving a transplanted liver. Because of the advancement in imaging the status of the portal vein is usually not in question. Rarely, the occasion arises when a liver is acutely available and circumstances have lead to doubt of the portal vein patency. The condition of these patients is often tenuous but a quick, reliable answer is essential to procuring the transplant.

If this situation arises, a fast, dependable and safe means for identifying the status of the portal vein is the simple placement of an innocuous 25 ga. spinal needle into the hepatic parenchyma without correction of coagulation or ascites. Because of CO2's low viscosity (1/400 of contrast), less invasive smaller needles can be used for administration. The low viscosity of CO2 when injected into the hepatic parenchyma dissipates into the sinusoids and takes the path of least resistance in the portal vein or its collaterals. Using DSA, these structures are easily and confidently visualized. Typically the intrahepatic portal veins are identified and CO2, which commonly refluxes, opacifies centrally demonstrating the main portal vein. Identification of cavernous transformation of the portal venous system is diagnostic of occlusion2. Additionally, using flexible small needles of this size eliminates the possibility of bleeding and traversing ascites is not an issue. Although rare, CO2 injections into the hepatic parenchyma can be used to quickly and safely identify the status of the portal vein potentially resulting in a curative procedure for that patient.

1. Radiotherapeutic Options for Hepatocellular Carcinoma with Portal Vein Tumor Thrombosis. Lee, D.S., Seong, J.; Liver Cancer. 2014 March; 3(1): 18-30. Review
2. Portal Vein Thrombosis: Prevalence, patient characteristics and lifetime risk: a population study based on 23,796 consecutive autopsies. Ogren, M., Bergqvist, D., Bjorck, M., Acosta, S., Eriksson, H., Sternby, N.H. World J Gastroenterology. 2006; 12: 2115-2119.
3. Carbon Dioxide Digital Subtraction Angiography (CO2 DSA): A comprehensive user guide for all operators. James G. Caridi MD FSIR, Kyung J. Cho MD FSIR, Christian Fauria MD, Navid Eghbalieh MD
4. Liver Transplantation for Hepatic Tumors: A Systemic Review. Ravaoli M, Ercolani G, Neri F, Coscon M, Stacchini G, Gaudio MD, Cucchetti A, Pinna AD.; World J Gastroenterology. 2014, May 14; 20(18):5345-5352.
5. Recommendations for Liver Transplantation for Hepatocellular Carcinoma: An International Consensus Conference Report. OLT for HCC Consensus Group: Clavien PA, Lesurtel M, Bossuyt PM, Gores GJ, Langer B, Perrier A.; Lancet Oncol. 2012 Jan;13(1): e11-22. doi: 10.1016/S 1470-2045(11)70175-9. Epub2011 Oct 31.
6. Liver Transplantation for Malignancy: Current Treatment strategies and Future Perspectives. Hackl C, Schlitt H, Kirchner G, Knoppke B, Loss M.; World J Gastroenterol. May 14, 2014, 20(18):5331-5344.

